

EndoSequence: Melding Endodontics With Restorative Dentistry, *Part 3*



Kenneth A.
Koch, DMD

This is Part 3 of a 3-part article series. Part 2 of Drs. Koch and Brave's article was published in the February 2009 issue of Dentistry Today and can be found in our archived articles at dentistrytoday.com. This, and all future articles that are presented in multiple parts, will now be available to our readers for review in their entirety at our Web site dentistrytoday.com. This is being done to help those readers who may have missed a portion of any multiple-part article, and will also facilitate the ability to review a complete article in its entirety for others.



Dennis Brave,
DDS

In parts 1 and 2 of this 3-part article series we discussed some of the ways endodontics melds with restorative dentistry. We also discussed the rationale behind, and the design features of, the EndoSequence (Brasseler USA) file. Additionally, we reviewed instrumentation techniques from both the basic and advanced perspectives. Progressing along this Endo-Restorative Continuum, we wish to now address obturation of the root canal space and introduce a new post concept.

... an endodontic system (EndoSequence) has been introduced that bridges the gap between root canal therapy and restorative dentistry.

OBTURATION

It is a continuing goal of Real World Endo to develop products and techniques that will deliver excellent endodontic results with optimal efficiency. An additional goal includes designing these techniques in such a way that the majority of practitioners will be able to predictably and successfully perform these procedures. The basic EndoSequence file system gives all clinicians the ability to machine predictable shapes that ultimately lead to synchronicity between the preparation and the master cone fit (Figure 1). Embracing this concept and taking it to

advanced levels in obturation, are sealer-based obturation systems based on glass ionomer (GI) and bioceramic technologies.

Glass Ionomer Obturation Technologies

Activ GP (Brasseler USA) is a system which utilizes improved GI technology—both as a sealer and as a special GI coated gutta-percha cone—to create a true single cone monobloc obturation (Figure 2). This is very significant because, for the first time, a true monobloc will allow us to create a hermetic seal within the root canal space. A hermetic seal has been a goal of endodontics for more than 50 years. Furthermore, a true single cone technique is a method that is now clinically achievable as a result of improved material science. More importantly, such a technique (when performed properly) will give the greatest percentage of clinicians the ability to produce superior obturation results.¹

In the original pursuit of this goal, GI (Ketac-Endo) was selected because of its superior biocompatibility and its physical properties. However, a problem historically with the early generations of GI and resin sealers was that neither method was able to develop a true monobloc. Although there were advocates on both sides of the argument, research has shown that both the GI and resins sealers have had some advantages and some limitations. However, there was one thing that both the resin and GI advocates could agree on—that obturation was headed in the direction of sealer based techniques rather than the mechanical packing and melting of gutta-percha. This made sense from both the technical and science sides.

It is also very interesting to see how the 2 materials differed. The resins were shown to have a good seal between the sealer and the gutta-percha cone, but their seal to the canal wall was questionable. On the other hand, GI cements displayed an excellent seal to the canal wall, but their seal to the gutta-percha was less than ideal. So as the 20th Century came to a close, we still found ourselves searching for a technique that could consistently deliver a true monobloc obturation.¹

Activ GP obturation is a single cone

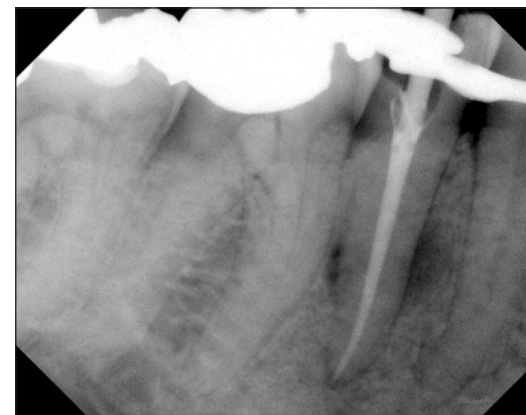

Figure 1a. Mandibular premolar demonstrating the precise synchronicity established between the last EndoSequence rotary file and master cone.

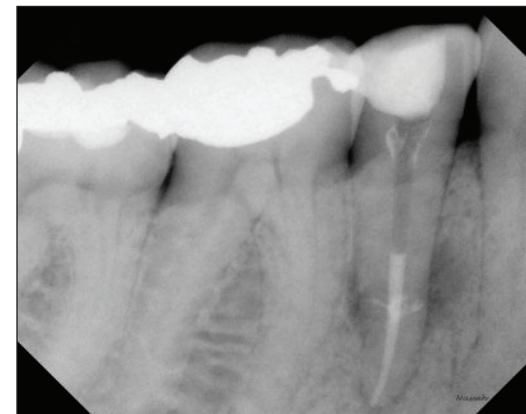

Figure 1b. Final obturator with burnout for post.

technique that requires a minimal amount of sealer rather than the excess that is utilized in other methods. This is because it involves a precision-based system. As previously mentioned, precision-based endodontics requires accuracy between the file and the master cone. Similar to the regular EndoSequence gutta-percha, all Activ GP points are laser-verified to precisely match the preparations made by the .04 or .06 tapered Endo-Sequence file system (Figure 3). The precision matching of the primary cone to the preparation (endodontic synchronicity) is very important with any single cone technique. This is because the accuracy of the cone fit to the preparation mini-

continued on page ##




Figure 2. Light refractive metallograph showing the relationship between the dentin, Activ GP Sealer (Brasseler USA), and the master cone. Note: this image demonstrates a monobloc obturation.



Figure 3. Activ GP (Brasseler USA) is available in a nonspill gutta-percha organizer.

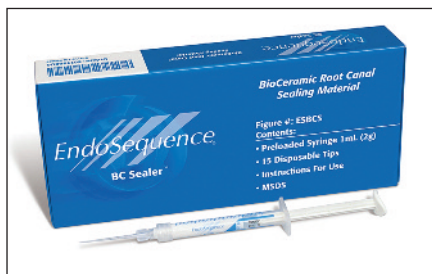

Figure 4. EndoSequence BC Sealer (Brasseler USA) is a new bioceramic sealer.

mizes the amount of sealer and any dimensional change. Although dimensional change can occur with all sealers, GI is very stable and does not shrink.

Furthermore, due to the predictability of shape associated with constant tapers, it may be stated that a true single cone technique should be accomplished with a constant tapered preparation such as a .04 or .06. A variable taper technique is not recommended because its lack of shaping predictability (and its corresponding lack of reproducibility) will lead to a less than ideal cone fit. This lack of endodontic synchronicity is why all variable taper preparations are associated with thermo-plastic techniques.

Bioceramic Obturation Technology

While GI has been a huge help in establishing a true single cone filling technique, the obturation equation

has further changed with the introduction of a new material (EndoSequence BC Sealer [Brasseler USA]), which utilizes bioceramic technology. However, before we discuss how this specific sealer is changing obturation, we need to address some of the merits associated with bioceramics.

The first question we need to ask ourselves is, “What are bioceramics?” Bioceramics are ceramic materials specifically designed for use in medicine and dentistry. They include alumina and zirconia, bioactive glass, glass ceramics, coatings and composites, hydroxyapatite and resorbable calcium phosphates, and radiotherapy glasses.²⁻⁴ Bioceramics are widely used for orthopedic applications, such as joint or tissue replacements, as a coating to improve the biocompatibility of metal implants, and they can also act as resorbable lattices providing a framework that is eventually dissolved as the body rebuilds tissue.

The properties associated with bioceramics make them very attractive to both medicine and dentistry. In addition to being nontoxic, bioceramics can be classified as:²⁻⁵

- *Bioinert*: noninteractive with biological systems.
- *Bioactive*: durable tissues that can undergo interfacial interactions with surrounding tissue.

There are numerous bioceramics currently in use in both dentistry and medicine, although more are used in medicine. Alumina and zirconia are among the bioinert ceramics used for prosthetic devices. Bioactive glasses and glass ceramics are available for use in dentistry under various trade names. In addition, porous ceramics such as calcium phosphate based materials have been used for filling bone defects. Also, some calcium silicates (MTA [DENTSPLY Tulsa Dental Specialties] and BioAggregate [DiaDent]) have been used in dentistry as root repair materials and for apical retrofills.

However, we must ask ourselves again, “What are the advantages of bioceramics in dental applications?” Clearly the first answer is related to physical properties. Bioceramics are exceedingly biocompatible, nontoxic, do not shrink, and are chemically stable within the biological environment. Secondly, and very important in endodontics, bioceramics will not result in a significant inflammatory response if an overfill occurs during the obturation process or in a root repair. A further advantage of the material itself is its ability to form hydroxyapatite and a bond between dentin and filling materials.

While the properties associated

with bioceramics make them very attractive to dentistry, in general, what would be their advantage if used as an endodontic sealer? From our perspective as clinicians, some of the advantages are: enhanced biocompatibility, possible increased strength of the root following obturation, high pH (12.9) during the setting process which is strongly antibacterial, sealing ability, and ease of use.⁶

The introduction of EndoSequence BC Sealer (Figure 4) allows us, for the first time, to take advantage of all the benefits associated with bioceramics; but to not limit its use to merely root repairs and apical retrofills. This is possible because of nanotechnology—the particle size of BC Sealer is so fine that it can actually be used with a capillary tip. This material has been designed as a nontoxic hydraulic calcium silicate cement that is easy to use as an endodontic sealer. The purpose of BC Sealer is to improve the convenience and delivery method of an excellent root canal sealer, while simultaneously utilizing the water inherent in the dentinal tubules to drive the hydration reaction of the material, thereby shortening the setting time. Dentin is composed of approximately 20% (by volume) water⁷, and it is this water which initiates the setting of the material and ultimately results in the formation of hydroxyapatite.

For clinical purposes, the advantages of a premixed endodontic cement (sealer) should be obvious. In addition to a significant saving of time and convenience, one of the major issues associated with the mixing of any cement, or sealer, is an insufficient and nonhomogenous mix, which ultimately may compromise the benefits associated with the material. Keeping this in mind, BC Sealer has been designed as a premixed bioceramic sealer that hardens only when exposed to a moist environment (produced by dentinal tubules).

The technique with this material is straightforward. Simply remove the syringe cap from the EndoSequence BC Sealer syringe and attach an Intra Canal Tip of your choice to the hub of the syringe. The Intra Canal Tip is flexible and can be bent to facilitate access to the root canal (Figure 5). Then, insert the tip of the syringe into the canal no deeper than the coronal one third. Gently and smoothly dispense a small amount (1 to 2 calibration markings) of EndoSequence BC Sealer into the root canal by compressing the plunger of the syringe. Using a No. 15 hand file or something comparable, lightly coat the canal walls with

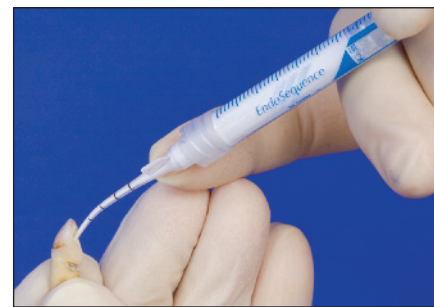

Figure 5. The intra canal tip can be precurved to expedite placement of the sealer.

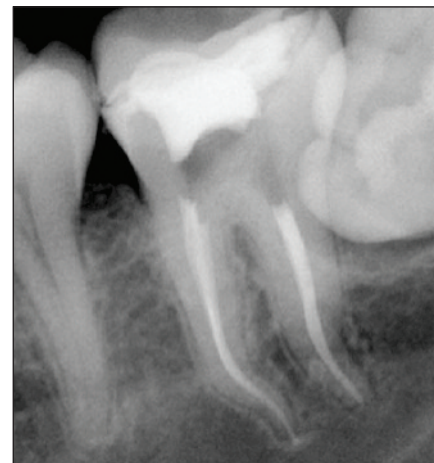

Figure 6. Post-op radiograph of a mandibular molar case with .04 tapers and BC Sealer. Notice the endodontic synchronicity of the preparation and obturation particularly in the mesial canals. Courtesy of Dr. Alex Fleury, Dallas.

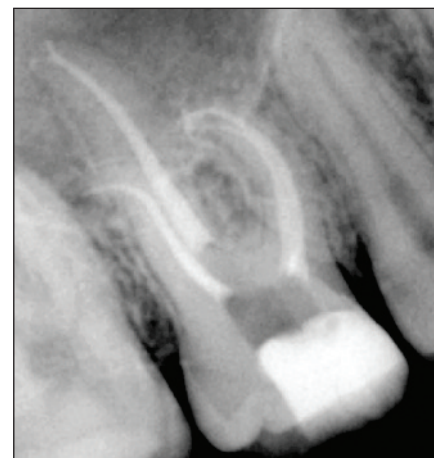


Figure 7. Post-op radiograph of maxillary molar with .04 tapers and BC Sealer. As evidence of the flow ability of this sealer, please note the sealed delta in the palatal root. Courtesy of Dr. Alex Fleury, Dallas.

the existing sealer in the canal. Next, coat the master gutta-percha cone with a thin layer of sealer and then very slowly insert it into the canal. The synchronized master gutta-percha cone will carry sufficient material to seal the apex.

The precise fit of the EndoSequence gutta-percha master cone (in combination with a constant taper preparation) creates excellent hydraulics and, for that reason, it is recommended that the practitioner use only a *small* amount of sealer. Furthermore, as with all obturation

continued on page XX

Xxxx...

continued from page

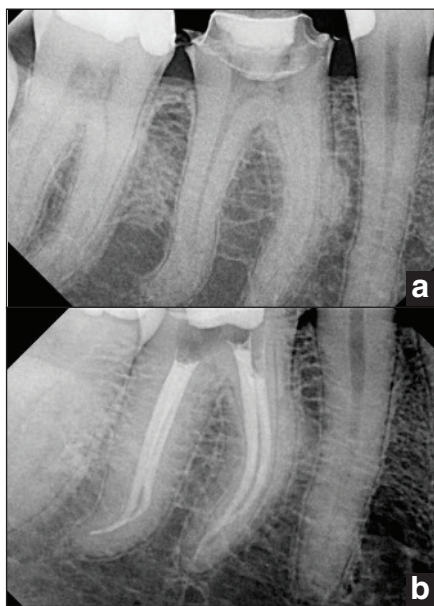


Figure 8. Pre- and post-op radiographs of a mandibular molar with .04 taper preparations and BC Sealer. Courtesy of Dr. Ali Nasseh, Boston.

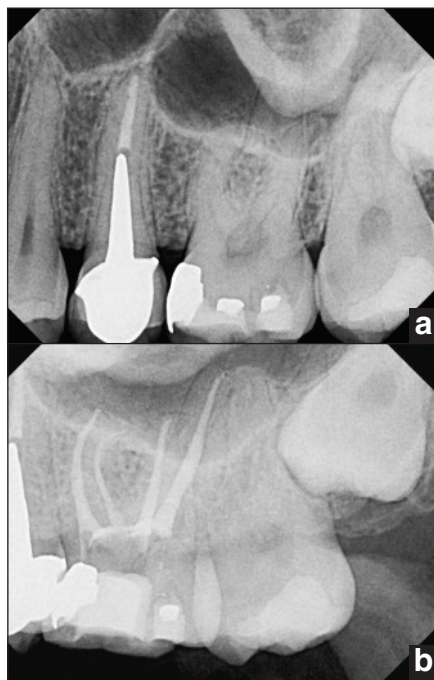


Figure 9. Pre- and post-op radiographs of a maxillary molar with .04 tapers and BC Sealer. Courtesy of Dr. Ali Nasseh, Boston.

techniques, it is important to insert the master cone *slowly* to its final working length. Finally, here's more good news. The glass components in the bioceramic sealer *bond* to the Activ GP GI coated cones.

IMPORTANCE OF A TRUE SINGLE CONE TECHNIQUE

When we talk about a true single cone technique let's think about what this really means. The easiest way to comprehend this is to compare it to carrier-based techniques. In these techniques, you heat the obturator and then insert it into the tooth, delivering it to a point just shy of the working length. Basically, you

are using a hard plastic carrier to deliver heated gutta-percha (or resin) into the root canal system. The primary limitation associated with this technique is the concern of stripping (denuding) the carrier of gutta-percha (or resin) when it is inserted into the canal orifice. Additionally, there is a lack of apical control that is the result of using heated gutta-percha (or resin). However, the concept of filling a root canal with a device that you can "feel" is admirable. It is essentially the same with an Activ GP cone and BC Sealer, but with a few differences. Again think about what you are actually doing. In essence, you are using a stiff carrier (one that is actually a stiffer gutta-percha cone) to deliver a dimensionally stable bioceramic sealer into the root canal system. So, while you get the "feel" of a carrier-based technique, you have the advantage of using gutta-percha as a carrier to deliver sealer. After all, it is *the sealer that creates the seal in obturation*, not heated gutta-percha. Additionally, post preparation will be a lot easier because you are now removing gutta-percha, *not* cutting plastic.

The 5 cases seen in figures 6 to 9 evidence the results of Activ GP cones used with BC Sealer.

RETREATMENT

Retreatment also remains an important aspect of advanced endodontic therapy. It is an area where an efficient instrument excels. Dr. Wayne Pulver (oral communication, March 2008), an endodontist in Ontario, Canada, describes retreatment with EndoSequence in the following manner. "Retreatment of plastic filling materials such as gutta-percha can be readily accomplished using the EndoSequence instruments. The bulk of the filling material can be removed with the use of a heated instrument, such as the 'Touch'n Heat' by SybronEndo, or the use of Gates Glidden drills in a crown down technique: No. 4, No. 3, No. 2. Avoid the use of large Gates Gliddens such as Nos. 5 and 6 except in very large canals because these instruments may over enlarge the coronal part of the canal. The use of solvents can expedite the process. However, judicious use is suggested because excess solvent can cause periapical inflammation and potential postoperative discomfort. If used, the solvent should be placed using a tuberculin syringe to control how much is placed into the chamber of the tooth."

Dr. Pulver goes on to say, "Once the bulk of the material is removed, the EndoSequence files can now be introduced into the tooth. Depending

on the size of the canal, .06 tapers work best except in very fine canals. The EndoSequence file design is ideal for gutta-percha removal. The instrument is a true reamer with a noncutting tip. The instrument should be used in a crown down technique. In most canals, the No. 30 .06 is the first instrument to be used. Using a torque control motor at 500 rpm, the file is taken to resistance and withdrawn slightly and then it is reinserted 3 times, advancing it approximately 1 mm each time. Proceed apically using the same technique with the No. 25 and No. 20 .06 files. Once the instrumentation is within 5 mm of the apex, consider the final removal of the plastic material with hand files and solvent. This will create a glide path which will allow for final instrumentation using the No. 30, No. 25, and No. 20 Sequence files."

Dr. Pulver has given some excellent clinical tips how to facilitate the retreatment of gutta-percha. Notice that he takes the first file in retreatment to resistance, rather than engagement. Thereafter, he takes each file to engagement which is about 1 mm each time.

Dr. Ali Nasseh, an endodontist in Boston, has also addressed the question of retreatment of bioceramic sealer cases. Historically, there had been confusion about retreatment GI endodontic cases (GI sealer is definitely retreatable when used as a sealer⁸) and similarly, there has also been confusion concerning the retreatability of bioceramics. The key is using bioceramics as a sealer, not a filler. This is why endodontic synchronicity is so important. And again, this is also why the use of constant tapers makes so much sense by minimizing the amount of endodontic sealer thereby facilitating retreatment.

The technique is relatively straightforward, as Dr. Nasseh (oral communication, December 2008) describes it:

"The key in retreatment bioceramic cases is to use an ultrasonic with a copious amount of water. This is particularly important at the start of the procedure in the coronal third of the tooth. Work the ultrasonic (with lots of water) down the canal to approximately half its length. At this point, add a solvent to the canal (chloroform) and switch over to an EndoSequence file (No. 30 or 35/.04 taper) run at an increased rate of speed (1,000 rpm). Proceed with this file, all the way to the working length, using solvent when indicated. An alternative is to use hand files for the final 2 to 3 mm and then follow the gutta-percha removal with a rotary file to ensure synchronicity."

The case seen in Figure 10

demonstrates the retreatment of BC Sealer.

A final aspect of the Endo-Restorative Continuum, and the one which ultimately melds restorative dentistry with endodontics, is the restoration of the endodontically treated tooth. It is well known and established that the ferrule effect (a minimum of 1.5 to 2.0 mm of vertical tooth structure at the gingival aspect of a crown preparation) is a key factor in the long-term success of these teeth.⁹ But let's examine something more basic regarding posts.

POSTS

It has been commonly accepted that all posts weaken teeth, and it is generally recognized that the main purpose of a post is to retain the core. Yet, post design as it relates to endodontic shaping, has become a confusing issue. Years ago there was a mantra in restorative dentistry, "tapered posts split roots." That was because all the specialists at the time were creating essentially parallel preparations with .02 taper hand files and if one inserted a tapered post into such a shape, you incurred the risk of splitting the tooth. Consequently, we used parallel posts. Then endodontic shaping evolved to the use of tapered preparations.

Today, while most practitioners are creating tapered endodontic preparations (constant or variable) many clinicians still are attempting to place parallel posts into these shapes. This likewise makes little sense and, as a result, clinicians are *excessively enlarging* their parallel post preps to gain some "bite" on the sides of the tapered canal walls. Unfortunately, the more coronal radicular dentin that has been removed, the less retentive is the final restoration. Additionally, this can also severely compromise the tooth and, as a result, we are witnessing many fractures emanating from the bottom of the posts (Figure 11). The net result is a diminished long-term prognosis. The answer to this dilemma is straightforward. *Use a post design that matches the shape of the endodontic preparation.* When one thinks about it, this is what cast posts were attempting to create—posts that precisely match the shape of the endodontic preparation!

A solution to this discrepancy between post size and canal shape has been achieved with the introduction of the EndoSequence Post System (Brasseler USA). The EndoSequence rotary file creates a fully tapered preparation (.04 or .06) from orifice to apex. The corresponding paper points and gutta-percha cones are laser verified to precisely match the shape created in the

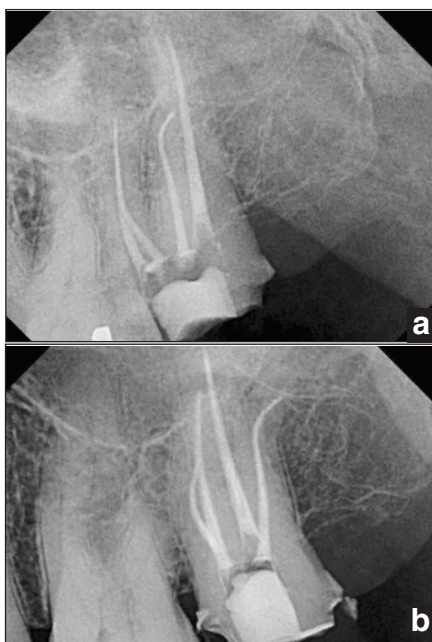


Figure 10. Pre- and post-op radiographs of a case initially obturated with Activ GP and BC Sealer and then retreated and obturated with the same technique. Courtesy of Dr. Ali Nasseh, Boston.

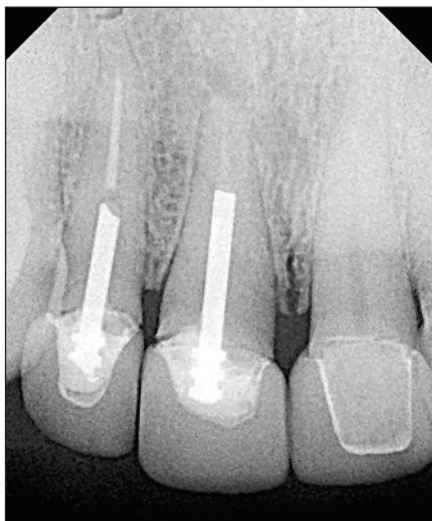


Figure 11. Fracture emanating from the bottom of a post.

canal. The EndoSequence post goes one step further and is likewise tapered (.04 or .06) to match the exact shape of the instrumented canal. Because of the synchronicity that has been established, there is no need to alter the shape of the root canal preparation to match the post (Figure 12). In a sense, the last rotary file taken to length is acting as a post drill.

This concept has also been addressed in a recent article by Dr. Richard Trushkowsky¹⁰ when he wrote, "The ideal post should have the same shape as the endodontic preparation, and should be noncorrosive, readily adjusted, and able to be removed without difficulty." Furthermore, since the dual cure resin cement that is used to bond the post to the canal wall is also the same material used to create the buildup (EndoSequence Build-up),

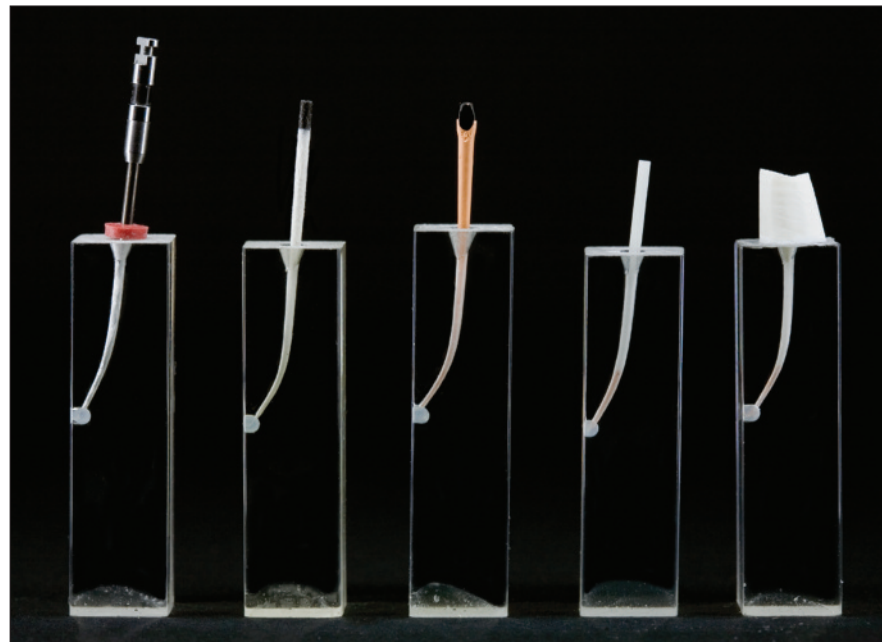


Figure 12. Complete endodontic synchronicity—from file through post placement (in blocks).

one can think of this technique as an intraradicular core buildup with a rebar. Not only is this "post technique" easy to replicate, it is kinder and much safer.

CONCLUSION

In this 3-part article series, a case has been made for the importance of maintaining endodontics as part of the treatment planning process and for performing endodontics in a more conservative fashion. When talking about doing "conservative endo," everyone thinks of coronal tooth structure, but it is the preservation of the radicular dentin (particularly in the coronal third of the root) that will enhance the long-term retention of the endodontically treated tooth.

Additionally, it has been emphasized in this article that we need to think in terms of an Endo-Restorative Continuum rather than just endodontics. Furthermore, an endodontic system (EndoSequence) has been introduced that bridges the gap between root canal therapy and restorative dentistry. This is significant because this "melding" of endodontics with restorative dentistry now gives you the ability to offer your patients endodontic therapy that will stand the test of time. ♦

References

1. Koch K, Brave D. A new endodontic obturation technique. *Dent Today*. May 2006;25:102-107.
2. Best SM, Porter AE, Thian ES, et al. Bioceramics: past, present and for the future. *J Eur Ceramic Soc*. 2008;28:1319-1327.
3. Dubok VA. Bioceramics: yesterday, today, tomorrow. *Powder Metallurgy and Metal Ceramics*. 2000;39:381-394.
4. Hench LL. Bioceramics: from concept to clinic. *J Am Ceram Soc*. 1991;74:1487-1510.
5. Hickman K. Bioceramics. CSA Web site. <http://www.csa.com/discoveryguides/archives/bioceramics.php>. Released April 1999; Accessed January 15, 2009.
6. Koch K, Brave D. A new day has dawned: the increased use of bioceramics in endodontics.

Dentaltown. In press.

7. Pashley DH. Dynamics of the pulpo-dentin complex. *Crit Rev Oral Biol Med*. 1996;7:104-133.
8. Friedman S, Moshonov J, Trope M. Residue of gutta-percha and a glass ionomer cement sealer following root canal retreatment. *Int Endod J*. 1993;26:169-172.
9. Schwartz RS, Robbins JW. Post placement and restoration of endodontically treated teeth: a literature review. *J Endod*. 2004;30:289-301.
10. Trushkowsky R. Fiber post selection and placement criteria: a review. *Inside Dentistry*. 2008;4:86-94.

Dr. Koch is the Founder and past director of the New Program in postdoctoral endodontics at the Harvard School of Dental Medicine. In addition to having maintained a private practice limited to endodontics, he has written numerous articles on endodontics and lecturers worldwide. He is a co-founder of Real World Endo and can be reached by visiting realworldendo.com.

Dr. Brave is a Diplomate of the American Board of Endodontics and is a member of the College of Diplomates. In endodontic practice for more than 25 years, he has lectured extensively on endodontics and holds several patents, including the VisiFrame. Formerly an associate clinical professor at the University of Pennsylvania, Dr. Brave currently holds a staff position at The Johns Hopkins Hospital. He is a co-founder of Real World Endo and can be reached by visiting realworldendo.com.

DISCLOSURE: Drs. Koch and Brave, in association with Brasseler USA, are the developers of the EndoSequence system.

Other articles linked in this series
can be found on
www.dentistrytoday.com